Multiple Nonprimary Motor Areas in the Human Cortex

GEREON R. FINK,[1] RICHARD S. J. FRACKOWIAK,[1] UWE PIETRZYK,[2]
AND RICHARD E. PASSINGHAM[1,3]
[1]*Wellcome Department of Cognitive Neurology, Institute of Neurology, London WC1N 3BG and Medical Research Council Clinical Sciences Centre, London W12 OHS;* [2]*Max-Planck Institute for Neurological Research, 50931 Cologne, Germany; and* [3]*Department of Experimental Psychology, University of Oxford, Oxford OX1 3UD, United Kingdom*

Fink, Gereon R., Richard S. J. Frackowiak, Uwe Pietrzyk, and Richard E. Passingham. Multiple nonprimary motor areas in the human cortex. *J. Neurophysiol.* 77: 2164–2174, 1997. We measured the distribution of regional cerebral blood flow with positron emission tomography while three subjects moved their hand, shoulder, or leg. The images were coregistered with each individual's anatomic magnetic resonance scans. The data were analyzed for each individual to avoid intersubject averaging and so to preserve individual gyral anatomy. Instead of inspecting all pixels, we prospectively restricted the data analysis to particular areas of interest. These were defined on basis of the anatomic and physiological literature on nonhuman primates. By examining only a subset of areas, we strengthened the power of the statistical analysis and thereby increased the confidence in reporting single subject data. On the lateral convexity, motor related activity was found for all three subjects in the primary motor cortex, lateral premotor cortex, and an opercular area within the premotor cortex. In addition, there was activation of somatosensory cortex (SI), the supplementary somatosensory area (SII) in the Sylvian fissure, and parietal association areas (Brodmann areas 5 and 40). There was also activation in the insula. We suggest that the activation in the dorsal premotor cortex may correspond with dorsal premotor area (PMd) as described in the macaque brain. We propose three hypotheses as to the probable location of vental premotor area (PMv) in the human brain. On the medial surface, motor-related activity was found for all three subjects in the leg areas of the primary motor cortex and somatosensory cortex and also activity for the hand, shoulder, and leg in the supplementary motor area (SMA) on the dorsal medial convexity and in three areas in the cingulate sulcus. We suggest that the three cingulate areas may correspond with rostral cingulate premotor area, dorsal cingulate motor area (CMAd), and ventral cingulate motor area (CMAv) as identified in the macaque brain. Somatotopic mapping was demonstrated in the primary motor and primary somatosensory cortex. In all three subjects, the arm region lay anterior to the leg region in parietal area 5. Also in all three subjects, the arm region lay anterior to the leg region in the supplementary motor cortex.

INTRODUCTION

Neurologists traditionally have referred to an area of the cerebral cortex as ''the motor cortex'' (Foerster 1936; Jackson 1875; Penfield and Boldrey 1938). It has been assumed that it is through this area in the precentral gyrus that the neocortex influences voluntary movement. However, more recent studies in nonhuman primates have made it clear that there are many nonprimary motor areas.

In 1952, Woolsey et al. stimulated the medial frontal surface with electrodes and identified an area that they termed the ''supplementary motor cortex.'' Subsequent studies have been able to identify several more nonprimary motor areas by using stimulation with microelectrodes, microelectrode recording, and anatomical tracing methods. Two important points have been established. First, it has been possible to show that in some of these areas there is a somatotopic map (Gentilucci et al. 1988; Godschalk et al. 1990; He et al. 1993; Kurata 1989; Luppino et al. 1991; Mitz and Wise 1987). Second, it has been shown that there are many nonprimary areas in the frontal lobe that send direct connections to the spinal cord (Dum and Strick 1991, 1993; He et al. 1993, 1995; Macpherson et al. 1982; Toyoshima and Sakai 1981; Wise 1996).

It recently has become possible to search for and locate these nonprimary motor areas in the human brain. Three advances have made this possible. First, anatomic studies are in progress identifying for the human brain the different subregions of the precentral cortex, using cytoarchitectonic and receptor mapping methods (Vogt et al. 1995; Zilles et al. 1996a). Second, functional brain imaging [positron emission tomography (PET) and functional magnetic resonance imaging (fMRI)] has advanced to a point at which the spatial resolution is such that it is possible to discriminate between peaks that are only a few millimeters apart (Fox et al. 1987; Rao et al. 1995; Shipp et al. 1995). Third, the sensitivity has improved such that it is possible to map activity in individual brains (Rao et al. 1993; Silbersweig et al. 1993; Townsend et al. 1991; Watson et al. 1993).

Our study differs from previous studies in several respects. First, though many group studies have been carried out using PET (Colebatch et al. 1991; Deiber et al. 1991; Luppino et al. 1991; Matelli et al. 1993; Remy et al. 1994), only a few papers have published data on individual subjects, with the activation coregistered onto MRI scans (Grafton et al. 1991, 1992, 1996; Rumeau et al. 1994). Of these, none draws distinctions between the various cingulate areas and premotor areas. Second, though there are several studies of individuals using fMRI (Kim et al. 1993a,b; Rao et al. 1995; Sanes et al. 1995), again only some of the nonprimary motor areas have been identified (Boecker et al. 1994; Rao et al. 1993). Finally, we identified the different areas by demonstrating that in each there was a representation of the hand, shoulder, and leg. In doing this, we followed the procedure used in anatomic studies by Strick and colleagues (Dum and Strick 1991, 1993; He et al. 1993, 1995). The advantage is that it is easier to distinguish between different areas if it is possible to identify each one by the fact that there is whole body-representation. Though several PET and fMRI studies have compared activations within motor cortex and the supplementary cortex for different body parts, none have done so for all the nonprimary motor areas.

 0022-3077/97 $5.00 Copyright © 1997 The American Physiological Society

In a recent paper, Picard and Strick (1996) have tried to identify all the nonprimary motor areas of the *medial* wall, including those in the cingulate sulcus. They summarize the data from many PET studies and present summary figures in which they plot the ''peak'' activations. Though the method has the advantage of pooling a large amount of data, there are two disadvantages. First, the studies were not uniform in their techniques for statistical analysis and anatomic localization. Second, many of the studies involved plotting the data for a group of subjects, and this is an insensitive method given the variation in anatomy between individuals. The gyral morphology even of the major gyri (e.g., pre- and postcentral gyrus) is variable in spite of normalization into a standard stereotactic space (Steinmetz et al. 1989; Talairach and Tournoux 1988); and this variation in gyral morphology can lead to a failure to detect signals when the data from individual subjects are pooled (Schlaug et al. 1994). In particular, the variation in sulcal pattern has been well documented for the medial frontal surface both in the monkey and the human brain (Paus et al. 1996; Vogt et al.1995); and it is on this surface that many of the nonprimary motor areas have been demonstrated in the macaque brain (Dum and Strick 1993).

The present study used a more sensitive method. First, we mapped these areas independently in three individuals using a PET camera in three-dimensional (3-D) mode (Spinks et al. 1992; Townsend et al. 1991). In this way, we could check the results by seeing to what extent they could be replicated in different brains. Second, we coregistered the PET data for each individual on MRI scans showing each individual's gyral morphology. Finally, instead of inspecting all pixels, we prospectively restricted the data analysis to particular areas of interest. These were defined on basis of the anatomic and physiological literature on nonhuman primates. For example, on the medial surface, we confined the analysis to the cingulate sulcus and to the convexity cortex above it, and we looked for those areas that had been identified in macaques by Luppino et al. (1991) and Dum and Strick (1993). By examining only a subset of areas, we strengthened the power of the statistical analysis and thereby increased the confidence in reporting single subject data (Friston et al. 1991; Townsend et al. 1991; Watson et al. 1993).

METHODS

Subjects and procedure

We scanned three normal healthy subjects (30- to 45-yr-old, right-handed males) in four conditions. In the first, they flexed and extended their right knee; the movements were paced by a metronome at a 1-Hz frequency, and the angle of flexion was between 60 and 100°. In the second, they abducted and adducted their right arm; the angle was between 30 and 90°. In the third condition, they flexed and extended the fingers of their right hand; digits 2–5 were moved together, and the angle of flexion was between 20 and 90°. In the control condition, the subjects lay at rest. Each task was performed four times by each subject in a randomized order to avoid order and habituation effects.

We used appropriate supports to minimize the movements of other body parts. This was of particular importance for the head. Before the study, the movements were videoed during task performance, and the head movements were measured to be $\leq$2 mm.

Scanning

We used a Siemens CTI 953 B PET scanner (CTI, Knoxville, TN), and the sensitivity was increased by recording in 3-D mode (Townsend et al. 1991). Relative regional cerebral blood flow (rCBF) was measured from the distribution of radioactivity (Mazziotta et al. 1985) after a slow bolus intravenous injection (Silbersweig et al. 1993) of $H_2{}^{15}O$ (12 mCi per scan). Attenuation-corrected data were reconstructed to 31 transaxial planes. The resulting resolution was 8.5 $\times$ 8.5 $\times$ 6 mm at full-width half-maximum (FWHM). The imaged brain volume extended from the vertex to the upper cerebellum. For each individual, magnetic resonance (MR) images were obtained with a 1 T Picker HPQ Vista system (resolution 1.3 $\times$ 1.3 $\times$ 1.3 mm) for PET-to-MRI image coregistration (see below).

Informed written consent was obtained from all volunteers. Ethical approval was provided by the Medical Ethics Committee of the Royal Postgraduate Medical School, Hammersmith Hospital, and permission to administer radioactivity by the Administration of Radioactive Substances Advisory Committee of the United Kingdom.

Image processing and data analysis

Images were processed using ANALYZE (BRU, Mayo Foundation, Rochester, MN) and MPM (Pietrzyk et al. 1994). Statistical analysis was performed in PROMATLAB (Math Works, Natick, MA) using Statistical Parametric Mapping (SPM, Wellcome Department of Cognitive Neurology & MRC Clinical Sciences Centre, London, UK).

The data for each individual subject were analyzed in the following way: all PET scans were realigned to the first emission scan to correct for any head movement (Woods et al. 1992), and a mean PET image was calculated for that individual. The MR image for that individual was aligned parallel with the intercommissural line (AC-PC line).The PET mean image for that individual then was coregistered with the MR image and thus realigned parallel with the intercommissural line (AC-PC line) (Woods et al. 1993). The PET images for each run were then resliced using the same algorithm. The correctness of the automated realignment procedure was checked using ANALYZE and MPM.

The PET images then were filtered using a low-pass Gaussian filter (FWHM 10 $\times$ 10 $\times$ 12 mm) to smooth the data in 3-D and so improve the signal-to-noise ratio (Friston et al. 1991). A pixel-based analysis of covariance with global activity as the covariate (Friston et al. 1990) controlled for systematic state-dependent differences in global blood flow associated with the different conditions. Then the mean values were calculated for each pixel across all scans per condition; this was done for the control (resting), and the three activation tasks separately. Comparisons of the means thereafter were made using *t*-statistics (Friston et al. 1991), subsequently transformed into normally distributed Z statistics (Friston et al. 1991).

The resulting set of Z-values constituted a statistical parametric map (SPM{z}-map) (Friston et al. 1991), which showed areas of significant relative rCBF change ($P < 0.01$, uncorrected) associated with the differences between each movement task and the resting state (Friston et al. 1991). As described below, the search for local maxima was limited to a subset of regions. Areas of relative rCBF change with $0.05 > P > 0.01$ were accepted as trends. Uncorrected *P* values were accepted because only a limited subset of the image data was interrogated [activations outside the predefined areas of interest were rejected (Friston et al. 1991)]. In the present paper, the terms local maxima or peaks refer to those points at which the activation was most statistically robust.

After coregistration of SPM{z}-maps with MR images, the exact anatomic location of the local maxima was identified for each individual with reference to the gyral anatomy identified on

each individual's coronal, sagittal, and transaxial MR images. As explained in the introduction, we used data from neuroanatomic and neurophysiological studies of human and nonhuman primates to guide the search for these maxima. The replicability of the results was checked by comparing the data for three different brains. We report local maxima of significant relative rCBF increases for the left hemisphere.

Identification of regions

The following regions were identified as areas of interest: *1*) motor cortex (MI) as the cortex lying within the anterior bank of the central sulcus; *2*) somatosensory cortex (SI) as the cortex lying within the posterior bank of the central sulcus and anterior to the postcentral sulcus; *3*) superior parietal area 5 as the cortex lying superior to the intraparietal sulcus, and immediately posterior to the postcentral sulcus; *4*) lateral premotor cortex as the cortex lying dorsally in or around the precentral sulcus; the border between areas 4 and 6 is variable (Zilles et al. 1996b), and we therefore have distinguished only between activations in the precentral sulcus (area 6) and the central sulcus (area 4); the anterior border of area 6 does not correspond to any sulcal boundary and we therefore searched anteriorly $\leq$10 mm in front of the precentral sulcus; *5*) the insula; *6*) the operculum as the cortex lying in the upper bank of the Sylvian, lateral to the insula, and anterior to the central sulcus; *7*) the secondary somatosensory area (SII) as the cortex lying in the upper bank of the Sylvian fissure, and immediately posterior to the central sulcus; *8*) the anterior inferior parietal cortex as the cortex lying below the intraparietal sulcus and posterior to the postcentral sulcus; *9*) the supplementary motor cortex as the cortex lying above the cingulate sulcus and anteriorly within the paracentral lobule; in addition, the cortex anterior to this also was searched up to the level of the genu of the corpus callosum; the posterior boundary between areas 4 and 6 was drawn at the sulcus just anterior to the central sulcus; and *10*) cingulate cortex as the cortex lying within the cingulate sulcus; for a subdivision of the areas within the cingulate, see DISCUSSION.

RESULTS

Relative rCBF increases were seen in motor and movement-related somatic areas. Figure 1 shows the areas of significant relative rCBF increase superimposed on a left paramedian sagittal MRI cut (−6 mm from the midline) and on two coronal MRI cuts (−1 mm and +5 mm relative to the vertical plane through the anterior commissure) of one subject when moving the leg.

On the parasagittal cut, significant increases in relative rCBF are seen in the anterior bank of the marginal ramus of the central sulcus (primary motor cortex), the supplementary motor area (SMA), and the anterior, posterior dorsal, and posterior ventral cingulate area. The figure also shows the peak for the somatosensory cortex (SI) in the posterior bank of the marginal ramus of the central sulcus. The coronal cuts show peaks in the insula (−1 mm) and the operculum (+5 mm). Table 1 gives the respective coordinates and *z* values for the maxima.

Figure 2 shows a projection of the local maxima of relative rCBF increase onto lateral and paramedian views of the left hemisphere of three subjects when moving the fingers, shoulder, and leg. As explained in the legend, this figure shows the maxima as projected onto the surface. Table 1 gives the respective coordinates and *z* values for the left hemisphere.

In the frontal lobe, the lateral views show motor related activity for all three subjects in the primary motor cortex, lateral premotor cortex, and an opercular area within the premotor cortex. This view also shows somatic areas: somatosensory cortex (SI), the supplementary somatosensory area (SII) in the Sylvian fissure, and parietal association areas (Brodmann areas 5 and 40). There is also activation in the insula. The medial views show motor related activity in all three subjects in the leg areas of the primary motor cortex and somatosensory cortex, and also activity for the hand, shoulder, and leg in the supplementary motor area (SMA) on the dorsal medial convexity and in three premotor areas in the cingulate sulcus.

DISCUSSION

Before interpreting the data, it is important to comment on two methodological issues. The first is the spatial resolution of the method. The second concerns the replicability of the data from brain to brain.

It might be thought that the precision with which the local ''maxima'' are reported is not in keeping with the spatial resolution of the PET images ($8.5 \times 8.5 \times 6$ mm at FWHM). However, it is essential to distinguish between the spatial resolution of the image *within* a scan and the ability to distinguish between local maxima if they come from *different* scans. It has been demonstrated that peaks from different scans can be distinguished even if they are separated by 2–3 mm (Fox et al. 1987; Shipp et al. 1995).

Within a scan, we have not attempted to distinguish peaks if they are less than the FWHM apart. The exceptions are the peaks in motor cortex and somatosensory cortex. For example, for *subject 1*, the peaks for the shoulder lie 5 mm apart in the *y* axis (Table 1). Yet, they are located in different banks of the central sulcus, and the separation also can be demonstrated in the other subjects.

Because we coregistered SPM{z}-maps on to each individual's MR image, we were able to localize the exact anatomic position of the local maxima in all three dimensions; thus in coronal or sagittal sections, we could judge whether the local maxima lay in the upper or lower banks of a sulcus. For example, a comparison of the activations in the left Sylvian fissure, as shown in the coronal sections in Fig. 1, allows a clear distinction to be drawn between the peak lying in the upper bank of the frontal operculum (*top right*) and the peak lying in the insula (*top left*). Similarly, it will be seen that the medial activations lie within the cingulate sulcus. Such judgements cannot be made if the peaks are plotted on standard brain diagrams (Grafton et al. 1993; Matelli et al. 1993). As discussed in a later section, a comparison of the different brains in the present study indicates that some of the variability in the precise anatomic location of the local maxima reflects variability in the gyral morphology.

The issue of replicability of the data is not the same as the issue of the variability in the exact location of the different areas in brains with differing gyral morphology. Rather, the comparison between the different brains allows us to validate the method used for data analysis. In searching for the various areas, we used a criterion of $P < 0.01$. The reason is that we wished to employ as sensitive a method as possible so as to avoid false negatives. The justification was that the area searched was a delimited area decided

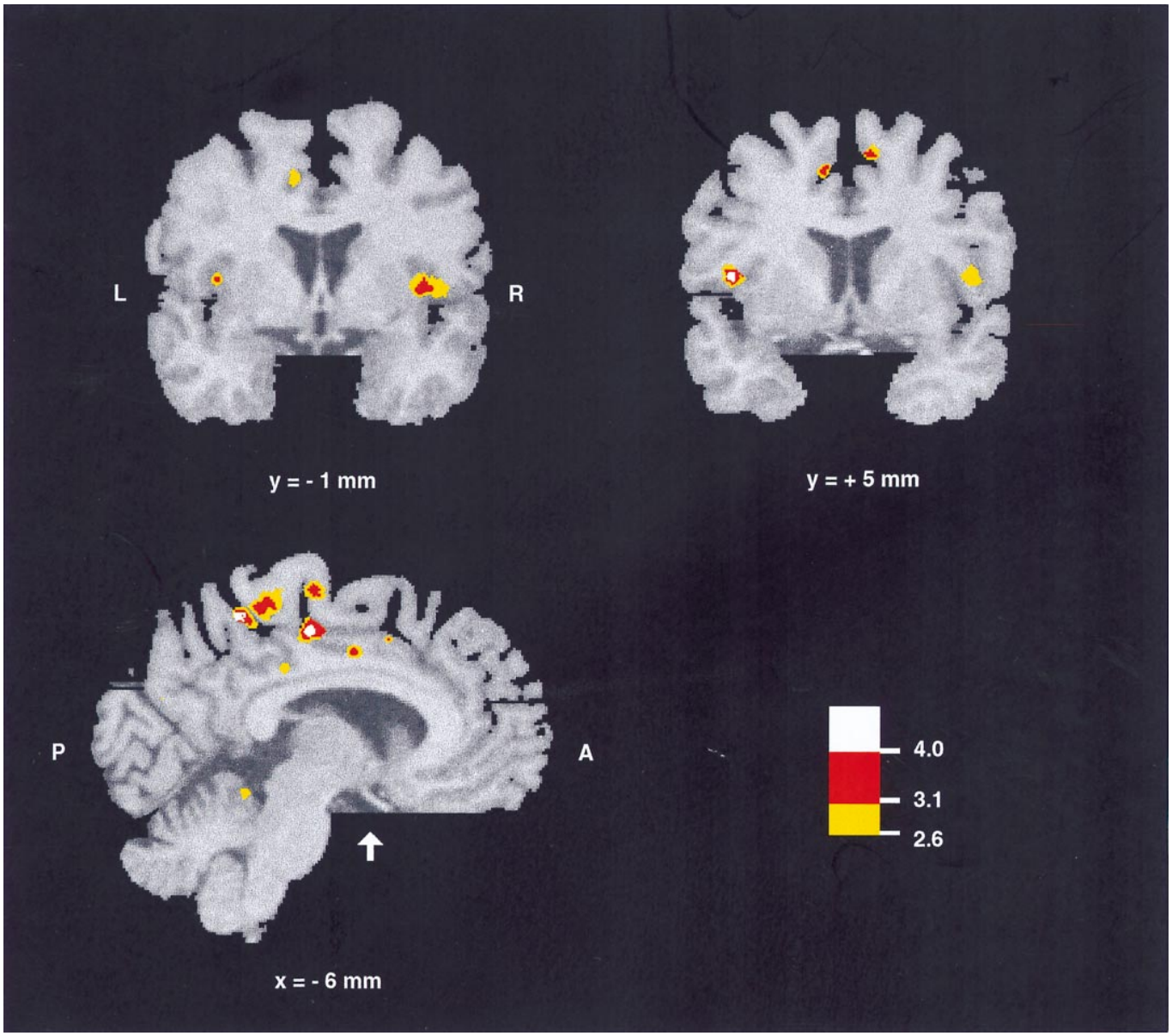

FIG. 1. Data for areas of significant relative regional cerebral blood flow (rCBF) increase for *subject 1* during movement of right leg after coregistration of SPM{z}-map on magnetic resonance (MR) image. *Lower*: parasagittal cut through left hemisphere (6 mm from midline); *upper*: coronal cuts (−1 mm and +5 mm relative to vertical plane through anterior commissure). Color scale gives the *z* values. ↑, anterior commissure. Paramedian image shows ''peaks'' within areas of significant relative rCBF increase for primary motor and primary somatosensory cortex, supplementary motor cortex (SMA) proper, rostral, dorsal, and ventral posterior cingulate areas. Coronal cuts show peaks for insula (−1 mm) and operculum (+5 mm).

before the analysis, on the basis of the data from nonhuman primates. The danger is that the analysis might turn up false positives, though previous studies suggest that this level of significance is adequate to avoid false positives (Dettmers et al. 1995; Watson et al. 1993).

The danger of false positives and false negatives can be assessed by carrying out replications. Table 1 shows that we were able to find representations of the finger, shoulder, and leg in most areas for most subjects. Where we were not able to do so, for example for the hand and shoulder in the ventral cingulate area for *subject 1*, the problem may be that we are using a method that is at the limits of its sensitivity. There is a limit to the radiation that can be given to a subject with PET.

Motor cortex

In all three subjects, the peaks for motor cortex lie within the anterior bank of the central sulcus. Zilles et al. (1996a,b) differentiate between area 4a and 4p. The peaks for the finger and shoulder lie near the convexity within the sulcus, suggesting that they lie within 4a. However, given the variability in the extent of area 4 (Roland and Zilles 1994; Zilles et al. 1996a,b), one would need a probability atlas to make this assignment with any degree of confidence.

Lateral premotor areas

The aim of the study was to search in the human brain for the nonprimary motor areas that have been demonstrated in

TABLE 1. *Coordinates of local maxima*

Region	Subject 1				Subject 2				Subject 3			
	x	*y*	*z*	*z* score	*x*	*y*	*z*	*z* score	*x*	*y*	*z*	*z* score
Motor cortex (BA 4) +												
Finger	−38	−22	60	4.96	−38	−25	50	4.12	−37	−31	66	4.44
Shoulder	−27	−24	64	4.48	−30	−32	64	3.48	−35	−35	67	3.72
Leg	−3	−37	59	3.88	−6	−40	52	4.48	−5	−36	56	3.25
Sensory cortex (BA 3, 1, 2) Δ												
Finger	−39	−25	61	4.60	−52	−28	50	3.64	−38	−38	69	4.00
Shoulder	−29	−29	64	4.12	−36	−39	58	3.72	−32	−42	60	3.10
Leg	−8	−45	55	4.52	−12	−47	66	4.12	−5	−48	52	4.12
Superior parietal (BA 5) *												
Finger	−33	−45	63	3.09	−40	−53	50	3.76	−38	−52	59	2.72
Shoulder	−35	−50	65	3.60	−34	−58	47	3.04	−23	−54	61	3.80
Leg	−4	−56	70	3.24	−27	−62	52	2.40	−18	−58	62	3.52
Premotor (BA 6) ×												
Finger					−35	−14	59	3.68	−28	−1	68	3.16
	−33	−3	60	3.80	−33	−9	46	3.08	−37	−7	64	2.92
Shoulder	−22	−12	67	4.36	−38	−8	53	2.80	−21	−2	61	3.44
	−32	−4	55	3.40	−44	−20	38	2.80	−25	−7	59	2.84
Leg	−26	−10	68	3.09	−39	−13	53	1.88	−38	−12	71	2.32
	−32	−5	56	3.20	−35	−13	47	2.12	−28	−8	64	2.60
Insula ▷												
Finger	−39	−2	0	3.16	−34	−8	−3	1.92	−43	−12	10	2.80
Shoulder	−41	−7	4	3.12	−34	−20	−2	2.60				
Leg	−40	−1	−1	3.12	−34	−16	−2	3.40	−57	−3	7	2.80
Operculum (upper bank) ▷												
Finger	−46	5	7	3.88	−52	3	−4	2.20	−61	4	13	3.72
Shoulder	−44	3	12	3.84	−55	1	−2	2.52	−47	6	3	2.52
Leg	−43	5	11	4.02	−52	−3	−2	3.32	−51	4	3	3.16
SII (upper bank of sylvian fissure) ◇												
Finger	−50	−17	20	3.52	−63	−26	9	2.60	−67	−20	10	2.16
Shoulder	−43	−25	21	3.32								
Leg	−44	−28	20	3.60	−57	−34	18	2.72	−39	−12	9	1.62
Inferior parietal (BA 40) □												
Finger	−49	−32	32	3.31	−59	−30	25	2.52	−62	−42	37	3.32
Shoulder	−48	−32	30	4.32	−61	−25	33	1.80	−44	−38	36	2.80
Leg	−49	−33	30	3.04	−47	−29	31	2.60	−63	−41	38	3.00
SMA (BA 6) □												
Finger	−5	−16	67	3.09	−2	−12	67	2.64	−1	−26	73	2.60
Shoulder	−3	−17	66	3.20	−7	−14	60	2.96				
Leg	−11	−20	62	3.96	−15	−15	66	3.96	−5	−29	67	3.20
Rostral cingulate area *												
Finger	−6	6	57	3.92	−5	14	52	2.20	−7	4	51	2.84
Shoulder	−7	8	50	3.32	0	1	47	2.32	−1	7	51	1.88
Leg	−8	11	40	3.40					−2	9	49	2.40
Dorsal cingulate area ×												
Finger					−3	−11	50	3.48	−5	−14	50	2.20
	−3	−29	57	3.52	−3	−30	51	3.28	−12	−21	60	2.32
Shoulder	−7	−16	51	3.96	−11	−10	50	3.56				
	−6	−21	49	3.60	−10	−23	52	3.62	−5	−21	56	2.32
Leg	−6	−3	42	3.60	−14	−8	47	3.24	−3	−10	50	2.88
	−6	−21	51	4.16	−6	−14	54	3.88	−6	−23	46	2.48
Ventral posterior cingulate area ▷												
Finger					−4	−31	46	2.88	−15	−30	40	2.84
Shoulder					−3	−32	47	2.52	−3	−36	40	2.60
Leg	−6	−34	36	2.6	−2	−30	46	3.00	−13	−30	38	2.80

Coordinates of local maxima of significant relative regional cerebral blood flow (rCBF) increase associated with flexion and extension of the fingers of the right hand, right shoulder, and right knee, as indicated by the highest *Z* score within an area. Anatomic locations are identified by inspection of the individual magnetic resonance image. Coordinates in millimeters: *x*, distance to right (+) or left (−) of midsagittal line; *y*, distance anterior (+) or posterior (−) to vertical plane through anterior commissure; *z*, distance above (+) or below (−) intercommissural (AC-PC) line. Coordinates refer to the local maxima of significant relative rCBF increase. For each area the symbol used in Fig. 2 is given. BA, estimate of the Brodmann area according to Talairach and Tournoux (1988). Omnibus correction: $P < 0.001$, $z > 3.1$; $P < 0.01$, $z > 2.3$; $P < 0.05$, $z > 1.6$. Motor cortex, +; sensory cortex, Δ; superior parietal, *; premotor, ×; insula, ▷; operculum, ▷; SII, ◇; inferior parietal, □; supplementary motor cortex (SMA), □; rostraul cingulate area, *, dorsal cingulate area, ×; ventral posterior cingulate area, ▷.

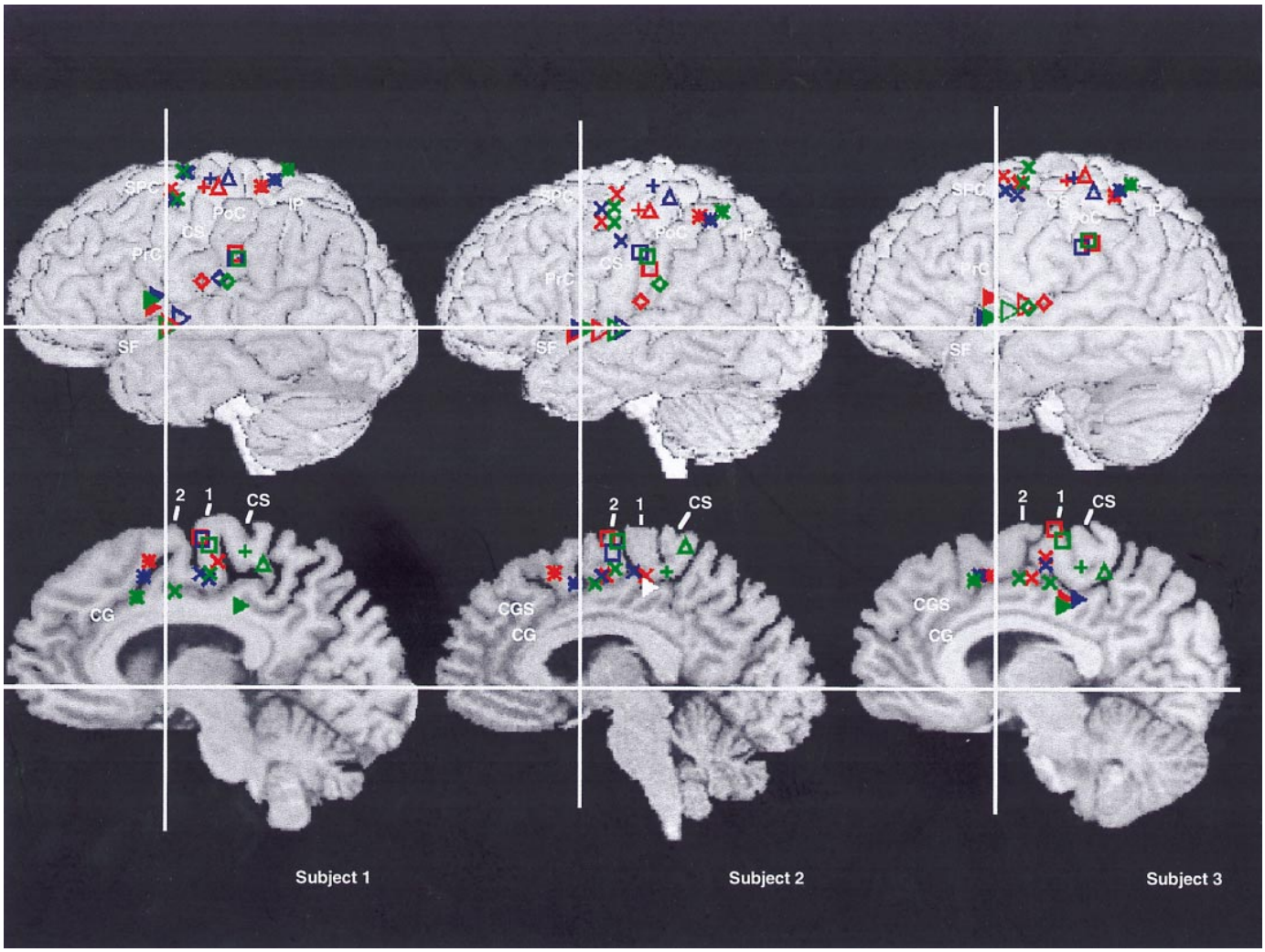

FIG. 2. Lateral surface projections (*top row*) and paramedian sagittal (6 mm to left of interhemispheric line) cuts (*bottom row*) of left hemispheres for 3 subjects. Onto these are projected local maxima of significant relative rCBF increases that are associated with flexion and extension of fingers of right hand (red), right shoulder (blue), and right knee (green). Local maxima were projected after coregistration of positron emission tomography (PET) and MR images. Displays demonstrate the individual relationship of PET activation foci relative to gyri and sulci at brain surface. It is important to note that this figure cannot give information about laterality of local maxima of relative rCBF increase. Furthermore, maxima are located on lateral surface even where they lie in deep sulci; for example, symbol for activation in insula appears on lateral surface. Because sulci do not always run parallel with surface, projection of maxima that lie in sulci can be misleading. Symbols used for different areas are given in Table 1. Note that some symbols are used on both lateral and medial views for noncorresponding areas and that white symbol indicates an identical site for 3 activation peaks. Sulci are labelled as follows: SPC, superior prefrontal (frontal) sulcus; PrC, precentral sulcus; CS, central sulcus; PoC, postcentral sulcus; IP, intraparietal sulcus; SF, Sylvian (lateral) fissure; CG, cingulate sulcus; CGs, superior cingulate sulcus; 1 and 2 label gyri anterior to motor cortex. For definition of areas, see METHODS.

the macaque brain. In each subject, there was activation of a dorsal region in area 6 on the lateral surface. The anterior-posterior coordinates lay within an area extending back between 10 and 20 mm from the vertical plane through the anterior commissure (VCA) line. We take this area to correspond to dorsal premotor area (PMd) in the macaque brain (He et al. 1993). Like PMd, it lies at roughly the dorsal-ventral level of the hand area of the motor cortex. In the human brain, the VCA line forms the border between area 6a alpha (behind) and 6a beta (in front) (Zilles et al. 1996a). On the lateral surface area, PMd lies behind the spur of the arcuate sulcus (di Pellegrino and Wise 1993a,b; Kurata 1989; Kurata and Hoffman 1994; Wise et al. 1996), and the spur is roughly at the level of the anterior commissure. PMd is located within the area identified as F2 on the basis of staining with cytochrome oxidase (Matelli et al. 1985, 1991).

There is a suggestion in the PET data that the peaks may subdivide into an anterior and a posterior cluster. However, there is no objective way of separating these activations into two groups. Given the way in which the peaks cluster, there is no way of deciding to which of the supposed subgroupings to allocate any particular peak. We therefore have decided to be conservative and to identify the whole as PMd.

In the macaque brain, there is a more ventral premotor area identified as ventral premotor area (PMv) (He et al. 1993; Muakassa and Strick 1979). This lies in and below the spur of the arcuate sulcus in area F4/F5 (Matelli et al. 1985, 1991). It is located at the level of the frontal eye-

fields as defined by microstimulation (Bruce et al. 1985). In PET studies, the frontal eye-fields have been identified as lying from 40 to 56 mm above the AC-PC line (Anderson et al. 1994; Fox et al. 1985; Paus 1996).

There are three hypotheses concerning the location of PMv in the human brain. The first is that it lies on the lateral surface at the level of the lower slices through the frontal eye-fields. Kawashima et al. (1995) scanned subjects while they learned to reach for targets, and there was activation as low as 38 and 44 mm above the AC-PC line. Grafton et al. (1994) scanned subjects while they performed a visual tracking task, and there was activation at a height of 36 mm above the AC-PC line.

In the present study, there was activation at a level of 38 mm above the AC-PC line for the shoulder in *subject 2*. However, most of the activations were at a higher level. This may be because the subjects performed with their eyes closed and did not reach for visual targets. In macaques, there are cells in the ventral premotor cortex that are active when monkeys reach for and grasp objects (Rizzolatti et al. 1987, 1988). Kurata (1994) argues that PMv is involved in the visual guidance of movement, and Kurata and Hoffmann (1994) have shown that if muscimol is applied to this region, the monkey makes spatial errors in reaching. However, Grafton et al. (1996) required subjects to reach for and grasp objects, and the peaks of activation were at +64 mm.

The second possibility is that PMv lies more ventrally and in opercular cortex. In the present study, there was an activation of a frontal opercular region, in an area that lies in the upper bank of the Sylvian fissure. It appears to lie behind the precentral sulcus, that is within area 6. A similar activation has been reported in previous studies in which subjects have been required to make movements (Fox et al. 1985; Stephan et al. 1995).

Finally it is possible that PMv extends into area 44, the region anterior to opercular area 6. No peak was found in area 44 in the present study in which subjects simply repeated movements. Activation has been reported in area 44 only when subjects imagine movement (Stephan et al. 1995), prepare for movement (Krams et al. 1996) or imitate movement (Rizzolatti et al. 1996). On the basis of cytoarchitecture Petrides and Pandya (1995) have identified area 44 in the macaque brain as lying in the posterior bank of the inferior ramus of the arcuate sulcus. It lies within area F5 as identified using cytochrome oxidase (Matelli et al. 1985).

Insula

In the present experiment, a final lateral area was identified in the insula. An activation in the general region of the insula has been claimed in previous studies (e.g., Chollet et al. 1991; Roland et al. 1991; Weiller et al. 1992). As in the earlier study by Stephan et al. (1995), the PET activations were coregistered onto the individual MRI scans, and in both studies, it is possible to distinguish an activation in the insula from an activation of opercular area 6. In the macaque monkey, there is an area in the anterior part of the sylvian fissure that sends projections to the spinal cord (Galea and Darian-Smith 1995).

Supplementary motor cortex

In all three subjects, there was activation of the medial frontal convexity above the cingulate sulcus. This lay behind the level of the VCA line and can thus be identified as the supplementary motor cortex (SMA).

There was no activation of the medial frontal convexity anterior to the VCA line. On the basis of cytoarchitecture Zilles et al. (1996a) have distinguished between the SMA and the ''pre-SMA'' (or anterior SMA) in the human brain. In the pre-SMA, there is a more pronounced lamination and a clearer demarcation of layer III from layer V. Zilles et al. (1996a) also identified the border at the level of the VCA line.

The pre-SMA has been activated only when subjects select among movements and prepare their movements (Deiber et al. 1991, 1996; Passingham 1996). Picard and Strick (1996) have reviewed the relevant evidence. The present study differs in that the subjects made the same movement on each trial and thus did not have to select between movements. It is this difference that probably accounts for the failure to activate the pre-SMA.

There has been a controversy concerning the ventral border of the SMA in the macaque brain. On the basis of microstimulation, Luppino et al. (1991) include parts of the upper bank of the cingulate gyrus in the SMA whereas on the basis of anatomic tracing Dum and Strick (1993) do not. It will be seen from Fig. 2 that in all three subjects there is a representation of the arm and leg that lies well above the cingulate sulcus. In early PET studies, it was not always obvious whether activation of the medial wall represented activation of the SMA, the cingulate cortex, or both (e.g., Colebatch et al. 1991; Deiber et al. 1991; Playford et al. 1992). Similarly, in the summary diagrams produced by Picard and Strick (1996), it is difficult to draw a clear border between the SMA and cingulate premotor areas. The distinction can only be drawn for certain if the activation is identified in single subjects and the PET data are coregistered onto individual MRI scans.

Cingulate motor areas

We have distinguished between three areas in the cingulate sulcus. The first lies anteriorly to the VCA line, and is termed the ''rostral cingulate area'' in Table 1. A similar area was identified in the group analysis of Picard and Strick (1996). However, there is considerable variability in the course of the cingulate sulcus in the human brain (Paus et al. 1996). Vogt et al. (1995) distinguish four patterns that are common; in some subjects there are two sulci anteriorly, one lying above the other, as in *subjects 2* and *3*. This means that it is only possible to be certain of locating the cingulate areas accurately if the analysis is done on single subjects and on the basis of their MR scans.

On the basis of anatomic tracing methods, Dum and Strick (1993) identify a rostral cingulate premotor area in the macaque brain that they term ''CMAr''. Using microstimulation Luppino et al. (1991) also identify a rostral cingulate area, and they allocate it to cytoarchitectonic area 24c. The area CMAr lies anterior to the level of the anterior commissure, and this leads us to suggest that the rostral cingulate area identified in the present study may correspond to CMAr. Vogt et al. (1995) also suggest that there may be a rostral cingulate area in area 24c in the human brain. Zilles et al. (1996a) distinguish two areas: cmr lying well anterior to the VCA line and cmc2 lying around the level of the VCA

line. It is not clear in which of these the rostral cingulate area of the present study should be taken to lie.

In many PET studies, a cingulate area that lies yet more anteriorly has been activated when subjects were required to select between responses to which they must attend. Frith and Grasby (1995) have plotted the results of several studies, including studies in which the responses were oculomotor or verbal (Paus et al. 1993). This area has been identified as lying in cytoarchitectonic area 32 (Deiber et al. 1991). It should be admitted, however, this allocation is not reliable because Vogt et al. (1995) have pointed out that the boundaries of area 32 are not accurately represented in the atlas of Talairach and Tournoux (1988). However, recently Paus et al. (1996) have provided a probability map of the medial surface, and it is clear that some of these activations lie within area 32.

Picard and Strick (1996) also have proposed that there are two separable cingulate areas in front of the VCA line, anterior rostral cingulate zone (RCZa) and posterior rostral cingulate zone (RCZp). In the present experiment, only the more posterior one was activated, perhaps because no response selection was required. Only the more posterior area can be regarded as a nonprimary motor area, because only this one is activated if subjects make movements but do not have to select between them.

In the present study, there was also activation in the dorsal bank of the cingulate sulcus behind the VCA line. The allocation to the dorsal bank was confirmed by inspecting coronal sections. In the macaque brain, the dorsal cingulate area of the present study lies within the caudal cingulate zone of Picard and Strick (1996). Luppino et al. (1991) used microstimulation to evoke movements from the dorsal bank, and they allocated some of the sites to the SMA proper (F3). However, they allocated others to cytoarchitectonic area 24d, which lies behind the level of the anterior commissure. On the basis of anatomic tracing, Dum and Strick (1991, 1993) identify an area that they call dorsal cingulate motor area (CMAd), and unlike Luppino et al. (1991), they take this to include most of the dorsal bank.

There is, however, an uncertainty in the PET data. As can be seen from Table 1 the data suggest two peaks for each body part (Fig. 2 and Table 1). In Fig. 2, for example, it will be seen that there appear to be two representations for the leg in the dorsal bank behind the VCA line. However, as for the lateral premotor cortex, there is no objective way of separating the activations into two groups. He et al. (1995) also reported that CMAd may contain two representations of the body, but, like us, they adopt a conservative interpretation and decide to identify just one area CMAd. There is overlap of the representations in the PET data, and we therefore must take them for the moment as one representation.

When discussing the SMA, Stephan et al. (1995) point out that in many subjects there are two gyri on the medial frontal surface in front of motor cortex and behind the VCA line. The authors argue that the PET data indicate that there may be more than one functional area on the convexity behind the VCA line. When discussing the cingulate areas, Zilles et al. (1996a) point out that a large part of their area cmc2 lies posteriorly to the VCA line and that area cmc1 also lies posteriorly to this line; they suggest that the caudal cingulate premotor region extends over both regions. It is possible that further PET or fMRI studies will indicate more than one representation behind the VCA line in these two regions.

The present study also identifies an activation in the ventral bank of the cingulate sulcus posteriorly. For *subject 1*, this was only found for the leg, but for the other subjects, peaks were identified for finger, shoulder, and leg. We take this area to be CMAv identified on the basis of anatomic tracing by Dum and Strick (1991, 1993). In the macaque brain, this lies in cingulate area 23. Vogt et al. (1995) also suggest that there is a ventral cingulate motor area in area 23c in the human brain. Picard and Strick (1996) comment that other studies have not found activation in this region with motor tasks. However, the activation is small, and it may not have been detected in other studies due to insensitive methods.

Sensory areas

There was also activation in SI, parietal area 5, and the anterior part of the inferior parietal cortex. It has been shown that in the macaque monkey there are direct projections to the spinal cord from SI, area 5, and the anterior part of the inferior parietal cortex (Galea and Darian-Smith 1995; Toyoshima and Sakai 1981). However, these projections are not heavy, and they distribute to the dorsal horn (Kuypers 1981). For this reason, they are not treated here as nonprimary *motor* areas.

Individual gyral anatomy

It will be seen from Fig. 2 that the three brains differ to some extent in gyral anatomy. This is evident, for example, on the medial surface. Using the nomenclature of Vogt et al. (1995), *subject 1* has a single, segmented cingulate sulcus, whereas *subjects 2* and *3* have a double (CGs and CG), nonsegmented cingulate sulcus. It will be seen that the rostral cingulate motor area lies within the anterior segment of the cingulate sulcus (CS1) in *subject 1* and in the lower of the two sulci (ie CG) in the other two subjects. There is no peak in the upper sulcus (CGs) in either of these two subjects. This contrasts with the findings for more complex tasks that are summarized by Paus et al. (1996); they suggest that on tasks such as the Stroop task the activation extends into Cgs. In *subject 1*, the dorsal cingulate area lies within CS2, and the ventral posterior cingulate area within CS3.

On the medial surface, Fig. 2 labels the gyri anterior to motor cortex and behind the VCA. We follow Stephan et al. (1995) in labeling these 1 and 2. In *subjects 1* and *3*, the peak for the SMA lies in gyrus 1. In *subject 2*, it appears to lie in gyrus 2, but we are unsure of the identification of the gyri. In all three subjects, the peaks for the SMA lay near a sulcus, as has been commented by Grafton et al. (1996).

On the lateral surface, the peaks assigned to PMd lie in the precentral sulcus, and roughly at the level of the superior prefrontal sulcus (SPC). This was also noted by Grafton et al. (1996). The peaks assigned to the upper bank of the anterior operculum are assumed to lie in area 6. In all three subjects, they lie at the level (anterior/posterior) of the ventral limb of the precentral sulcus. The peaks in the insula lie slightly more posteriorly, and in all three subjects, they are at the level (anterior/posterior) of the lower extension of the central sulcus.

Somatotopy

It was not the purpose of this study to examine somatotopy in detail. The reason for scanning while subjects moved their fingers, shoulder, or leg was that we wanted to distinguish areas with a whole body representation. However, the data allow certain limited comments on somatotopy. As in previous studies, PET proved adequate to demonstrate somatotopy in the motor cortex (Colebatch et al. 1991; Grafton et al. 1991, 1992). The distinction between hand and leg is clear cut (Grafton et al. 1991). The mapping within the forelimb is much less so (Colebatch et al. 1991; Grafton et al. 1992). In *subjects 1* and *2,* the peaks for hand and shoulder were clearly separate (11 mm apart in *x* coordinate in *subject 1;* 14 mm apart in the *z* coordinate in *subject 2*); but in *subject 3,* they were very close. Functional MRI has been used by Rao et al. (1995) to study hand and elbow and by Sanes et al. (1995) to study fingers and wrist, and both report considerable overlap in the representations. The present study aimed to locate local maxima within areas of activation, rather than to assess the extent of the activations and the degree of overlap of activations was therefore not assessed.

For many other areas, we have not been able to determine whether there is or is not somatotopy. This is because the relative locations of the peaks were not replicable from subject to subject. However, there are suggestive data for parietal area 5 and for the SMA. In all three subjects, the arm area lay in front of the leg area in parietal area 5 and a similar layout of the body has been shown in area 5 by anatomic tracing methods in the macaque brain (Pearson and Powell 1985).

There has been controversy over mapping in the SMA both in the animal and human literature. There is agreement that it is possible to identify an arm and leg area. Macpherson et al. (1982) claimed that there was considerable overlap of the arm and leg representation, but others have shown a clear rostral-caudal organization (Dum and Strick 1993; Luppino et al. 1991, 1994; Mitz and Wise 1987; Murray and Coulter 1981). Electrophysiological stimulation of the medial wall in patients also has suggested that there is a somatotopy, such that the leg representation is caudal to the arm representation (Fried 1996; Fried et al. 1991). However, it is not clear that these studies can distinguish accurately between maps in the SMA and the more ventral cingulate cortex. This can be done in PET. In the present study, there is a suggestion that there is somatotopy in the SMA. In all three subjects, the peak for the hand is anterior to the peak for the leg. Picard and Strick (1996) also have shown that the face area lies anteriorly to the arm area.

Grafton et al. (1993) also identified two representations of the body on the medial surface behind the VCA line and suggest that both are mapped. Matelli et al. (1993) also used PET and they claim no evidence of mapping in the SMA. However, they only compared movements of the fingers and shoulder, and they report group data in images that have been smoothed to a greater degree than in the present study.

There is agreement that in the macaque brain there is a representation of distal as well as proximal musculature of the forearm (Dum and Strick 1993; Luppino et al. 1991; Mitz and Wise 1987), but some have stressed the greater extent of the representation of the proximal musculature in microstimulation maps (Rizzolatti et al. 1996; Wiesendanger et al. 1996). In the present study, we found an activation for the fingers as well as for the shoulder.

Conclusions

We have used PET to identify the multiple nonprimary motor areas in the human brain. They are motor areas in the sense that they are activated when subjects execute simple movements and do not have to select between movements. In macaque monkeys, many of these areas can be shown to be premotor areas in the sense that they send projections to motor cortex. PET cannot be used to identify which areas are and which areas are not connected monosynaptically. However, PET can be used to identify corresponding areas in the human and macaque brain. This can be done by relating the activations to the location of sulci and by using cytoarchitectonic maps of the human brain (Vogt et al. 1995; Zilles et al. 1996a). Many of the areas identified in the present study appear to correspond to areas that are known to project both to motor cortex and the spinal cord in macaque monkeys (Dum and Strick 1991, 1993; Galea and Darian-Smith 1995; He et al. 1993, 1995; Leichnetz 1986; Muakassa and Strick 1979; Toyoshima and Sakai 1981).

Functional brain imaging also has been used to identify multiple visual areas (Sereno et al. 1995; Watson et al. 1993; Zeki et al. 1991). Studies of these visual areas in macaques strongly suggest functional specialization of the different areas (van Essen et al. 1993; Zeki 1993). The challenge is now to use functional brain imaging to demonstrate the ways in which the various nonprimary motor areas are specialized in the human brain.

We would like to thank the members of the PET methods and chemistry sections in the Medical Research Council Cyclotron Unit, Hammersmith Hospital, who made this work possible.

G. R. Fink and R.S.J. Frackowiak are supported by the Wellcome Trust.

Address for reprint requests: G. R. Fink, Wellcome Department of Cognitive Neurology, Institute of Neurology, 12 Queen Square, London WC1N 3BG, UK.

Received 14 June 1996; accepted in final form 18 December 1996.

REFERENCES

ANDERSON, T. J., JENKINS, I. H., BROOKS, D. J., HAWKEN, M. B., FRACKOWIAK, R.S.J., AND KENNARD, C. Cortical control of saccades and fixation in man: a PET study. *Brain* 117: 1073–1084, 1994.

BOECKER, H., KLEINSCHMIDT, A., REQUARDT, M., HAENICKE, W., MERBOLDT, K. D., AND FRAHM, J. Functional cooperativity of human cortical motor areas during self-paced simple finger movements. A high-resolution MRI study. *Brain* 117: 1231–1239, 1994.

BRUCE, C. J., GOLDBERG, M. E., BUSHNELL, M. C., AND STANTON, G. B. Primate frontal eye fields. II. Physiological and anatomical correlates of electrically evoked eye movements. *J. Neurophysiol*. 54: 714–734, 1985.

CHOLLET, F., DI PIERO, V. D., WISE, R.J.S., BROOKS, D. J., DOLAN, R. J., AND FRACKOWIAK, R.S.J. The functional anatomy of motor recovery after stroke in humans: a study with positron emission tomography. *Ann. Neurol.* 29: 63–71, 1991.

COLEBATCH, J. G., DEIBER, M.-P., PASSINGHAM, R. E., FRISTON, K. J., AND FRACKOWIAK, R.S.J. Regional cerebral blood flow during voluntary arm and hand movements in human subjects. *J. Neurophysiol.* 65: 1392–1401, 1991.

DEIBER, M.-P., IBANEZ, V., SADATO, N., AND HALLET, M. Cerebral structures participating in motor preparation in humans: a study with positron emission tomography. *J. Neurophysiol.* 75: 233–247, 1996.

DEIBER, M.-P., PASSINGHAM, R. E., COLEBATCH, J. G., FRISTON, K. J., NIXON, P. D., AND FRACKOWIAK, R.S.J. Cortical areas and the selection of movement: a study with positron emission tomography. *Exp. Brain Res.* 84: 393–402, 1991.

DETTMERS, C., FINK, G. R., LEMON, R. N., STEPHAN, K. M., PASSINGHAM, R. E., SILBERSWEIG, D., HOLMES, A., BROOKS, D. J., AND FRACKOWIAK, R.S.J. The relation between cerebral activity and force in the motor areas of the human brain. *J. Neurophysiol*. 74: 802–815, 1995.

DI PELLEGRINO, G. AND WISE, S. P. Visuospatial versus visuomotor activity in the premotor and prefrontal cortex of a primate. *J. Neurosci.* 13: 1227–1243, 1993a.

DI PELLEGRINO, G. AND WISE, S. P. Effects of attention on visuomotor activity in the premotor and prefrontal cortex of a primate. *Somatosens. Mot. Res.* 10: 245–262, 1993b.

DUM, R. P. AND STRICK, P. L. The origin of corticospinal projections from the premotor areas in the frontal lobe. *J. Neurosci.* 11: 667–689, 1991.

DUM, R. P. AND STRICK, P. L. Cingulate motor areas. In: *Cingulate Cortex and Limbic Thalamus: A Comprehensive Handbook*, edited by B. A. Vogt and M. Graybiel. Boston: Birkhauser, 1993, p. 415–441.

FOERSTER, O. Motorische Felder und Bahnen. Berlin: Springer, 1936.

FOX, P. T., FOX, J. M., RAICHLE, M. E., AND BURDE, R. M. The role of cerebral cortex in the generation of voluntary saccades: a positron emission tomography study. *J. Neurophysiol.* 54: 348–369, 1985.

FOX, P. T., MIEZIN, F. M., ALLMAN, J. M., VAN ESSEN, D. C., AND RAICHLE, M. E. Retinotopic organization of human visual cortex mapped with positron emission tomography. *J. Neurosci*. 7: 913–922, 1987.

FRIED, I. Electrical stimulation of the supplementary sensorimotor area. In: *Supplementary Sensorimotor Area*, edited by H. O. Lueders. Philadelphia: Lippincott-Raven, 1996, p. 177–186.

FRIED, I., KATZ, A., MCCARTHY, G., SASS, K. J., WILLIAMSON, P., AND SPENCER, S. S. Functional organization of human supplementary motor cortex studied by electrical stimulation. *J. Neurosci*. 11: 3656–3666, 1991.

FRISTON, K. J., FRITH, C. D., LIDDLE, P. F., DOLAN, R. J., LAMMERTSMA, A. A., AND FRACKOWIAK, R.S.J. The relationship between global and local changes in PET scans. *J. Cereb. Blood Flow Metab.* 10: 458–466, 1990.

FRISTON, K. J., FRITH, C. D., LIDDLE, P. F., AND FRACKOWIAK, R.S.J. Comparing functional (PET) images: the assessment of significant change. *J. Cereb. Blood Flow Metab.* 11: 690–699, 1991.

FRITH, C. D. AND GRASBY, P. M. rCBF studies of prefrontal function and their relevance to psychosis. In: *Handbook of Neuropsychology*, edited by F. Boller and J. Grafman. Elsevier Science B.V., 1995, p. 383–403.

GALEA, M. P. AND DARIAN-SMITH, I. Multiple corticospinal neuron populations in the macaque monkey specified by their unique cortical origins, spinal terminations and connections. *Cereb. Cortex* 4: 167–194, 1995.

GENTILUCCI, M., FOGASSI, L., LUPPINO, G., MATELLI, M., CAMARDA, R., AND RIZZOLATTI, G. Functional organization of inferior area 6 in the macaque monkey. I. Somatotopy and the control of proximal movements. *Exp. Brain Res.* 71: 475–490, 1988.

GEYER, S., LEDBERG, A., SCHLEICHER, A., KINOMURA, S., SCHORMANN, T., BUERGEL, U., KLINGBERG, T., LARSON, J., ZILLES, K., AND ROLAND, P. E. Two different areas within the primary motor cortex of man. *Nature Lond.* 382: 805–807, 1996.

GODSCHALK, M., MITZ, A. R., VAN DER BURG, J., AND VAN DUIN, B. Microstimulation map of the monkey premotor cortex. *Soc. Neurosci. Abstr.* 16: 1113, 1990.

GRAFTON, S. T., FAGG, A. H., WOODS, R. P., AND ARBIB, M. A. Functional anatomy of pointing and grasping in humans. *Cereb. Cortex* 6: 226–237, 1996.

GRAFTON, S. T., MAZZIOTTA, J. C., WOODS, R. P., AND PHELPS, M. E. Human functional anatomy of visually guided finger movements. *Brain* 115: 565–587, 1992.

GRAFTON, S. T., WOODS, R. P., AND MAZZIOTTA, J. C. Within-arm somatotopy in human motor areas determined by positron emission tomography imaging of cerebral blood flow. *Exp. Brain Res.* 95: 172–176, 1993.

GRAFTON, S. T., WOODS, R. P., MAZZIOTTA, J. C., AND PHELPS, M. E. Somatotopic mapping of the primary motor cortex in humans: activation studies with cerebral blood flow and positron emission tomography. *J. Neurophysiol.* 66: 735–743, 1991.

GRAFTON, S. T., WOODS, R. P., AND TYSZKA, J. M. Functional imaging of procedural motor learing: relating cerebral blood flow with individual subject performance. *Human Brain Mapping* 1: 221–234, 1994.

HE, S.-Q., DUM, R. P., AND STRICK, P. L. Topographic organization of corticospinal projections from the frontal lobe: motor areas on the lateral surface of the hemisphere. *J. Neurosci.* 13: 952–980, 1993.

HE, S.-Q., DUM, R. P., AND STRICK, P. L. Topographic organization of corticospinal projections from the frontal lobe: motor areas on the medial surface of the hemisphere. *J. Neurosci.* 15: 3284–3306, 1995.

JACKSON, J. H. Clinical and physiological researches on the nervous system. I. On the anatomical and physiological localization of movements in the brain. In: *Selected Writings*, edited by J. H. Jackson. London: Churchill, 1875, p. 33–76.

KAWASHIMA, R., ROLAND, P. E., AND O'SULLIVAN, B. T. Functional anatomy of reaching and visuomotor learning: a positron emission tomography study. *Cereb. Cortex* 2: 111–122, 1995.

KIM, S.-G., ASHE, J., GEORGOPOULOS, A. P., MERKLE, H., ELLERMANN, J. M., MENON, R. S., OGAWA, S., AND UGURBIL, K. Functional imaging of human motor cortex at high magnetic field. *J. Neurophysiol.* 69: 297–302, 1993a.

KIM, S. G., ASHE, J., HENDRICH, K., ELLERMANN, J. M., MERKLE, H., UGURBIL, K., AND GEORGOPOULOS, A. P. Functional magnetic resonance imaging of motor cortex: hemispheric asymmetry and handedness. *Science Wash. DC* 261: 615–617, 1993b.

KRAMS, M., RUSHWORTH, M., DEIBER, M.-P., FRACKOWIAK, R.S.J., AND PASSINGHAM, R. E. Broca's area and mental preparation of finger movements. *Exp. Brain Res.* (In press).

KURATA, K. Distribution of neurons with set- and movement-related activity before hand and foot movements in the premotor cortex of rhesus monkeys. *Exp. Brain Res.* 77: 245–256, 1989.

KURATA, K. Information processing for motor control in primate premotor cortex. *Behav. Brain Res.* 61: 135–142, 1994.

KURATA, K. AND HOFFMAN, D. S. Differential effects of muscimol microinjection into dorsal and ventral aspects of the premotor cortex of monkeys. *J. Neurophysiol.* 64: 1151–1164, 1994.

KUYPERS, H.G.J.M. Anatomy of descending pathways. In: *Handbook of Physiology. The Nervous System. Motor Control.* Bethesda, MD: Am. Physiol. Soc., 1981, sect. 1, vol. II, p. 597–666.

LEICHNETZ, G. R. Afferent and efferent connections of the dorsolateral precentral gyrus (area 4, hand/arm region) in the macaque monkey, with comparisons to area 8. *J. Comp. Neurol*. 254: 460–492, 1986.

LUPPINO, G., MATELLI, M., CAMARDA, R. M., GALLESE, V., AND RIZZOLATTI, G. Multiple representations of body movements in mesial area 6 and the adjacent cingulate cortex: an intracortical microstimulation study in the macaque monkey. *J. Comp. Neurol.* 311: 463–482, 1991.

LUPPINO, G., MATELLI, M., CAMARDA, R., AND RIZZOLATTI, G. Corticospinal projections from mesial frontal and cingulate areas in the monkey. *Neuroreport* 5: 2545–2548, 1994.

MACPHERSON, J. M., MARANGOZ, C., MILES, T. S., AND WIESENDANGER, M. Microstimulation of the supplementary motor area (SMA) in the awake monkey. *Exp. Brain Res.* 45: 410–416, 1982.

MATELLI, M., LUPPINO, G., AND RIZZOLATTI, G. Pattern of cytochrome oxidase activity in frontal agranular cortex of the macaque monkey. *Behav. Brain Res.* 18: 125–136, 1985.

MATELLI, M., LUPPINO, G., AND RIZZOLATTI, G. Architecture of superior and mesial area 6 and the adjacent cingulate cortex in the macaque monkey. *J. Comp. Neurol.* 311: 445–462, 1991.

MATELLI, M., RIZZOLATTI, G., BETTINARDI, V., GILARDI, M. C., PERANI, D., RIZZO, G., AND FAZIO, F. Activation of precentral and mesial motor areas during the execution of elementary proximal and distal arm movements: a PET study. *Neuroreport* 4: 1295–1298, 1993.

MAZZIOTTA, J. C., HUANG, S. C., PHELPS, M. E., CARSON, R. E., MACDONALD, N. S., AND MAHONEY, K. A non-invasive positron computed tomography technique using oxygen-15 labelled water for the evaluation of a neurobehavioral task battery. *J. Cereb. Blood Flow Metab.* 5: 70–78, 1985.

MITZ, A. R. AND WISE, S. P. The somatotopic organization of the supplementary motor area: intracortical microstimulation mapping. *J. Neurosci.* 7: 1010–1021, 1987.

MUAKASSA, K. F. AND STRICK, P. L. Frontal lobe inputs to primate motor cortex: evidence for four somatotopically organized ''premotor areas.'' *Brain Res*. 177: 176–182, 1979.

MURRAY, E. A. AND COULTER, J. D. Supplementary sensory areas: the medial parietal cortex in the monkey. In: *Cortical Sensory Organization: Multiple Somatic Areas*, edited by C. N. Woolsey. Clifton, NJ: Humana Press, 1981, p. 167–195.

PASSINGHAM, R. E. Functional specialization of the supplementary motor area in monkeys and humans. In: *Supplementary Sensorimotor Area*, edited by H. O. Luders. Philadelphia: Lippincott Raven, 1996, p. 105–116.

PAUS, T. Location and function of the human frontal eye field: a selective review. *Neuropsychologia* 34: 475–483, 1996.

PAUS, T., PETRIDES, M., EVANS, A. C., AND MEYER, E. Role of the human anterior cingulate cortex in the control of oculomotor, manual, and speech

responses: a positron emission tomography study. *J. Neurophysiol*. 70: 453–459, 1993.

PAUS, T., TOMAIUOLO, F., OTAKY, N., MACDONALD, D., PETRIDES, M., ATLAS, J., MORRIS, R., AND EVANS, A. C. Human cingulate and paracingulate sulci: pattern, variability, asymmetry and probabilistic map. *Cereb. Cortex* 6: 207–214, 1996.

PEARSON, R.C.A. AND POWELL, T.P.S. The projection of the primary sensory cortex upon area 5 in the monkey. *Brain Res.* 9: 89–103, 1985.

PENFIELD, W. AND BOLDREY, E. Somatic motor and sensory representation in the cerebral cortex of man as studied by electrical stimulation. *Brain* 15: 389–443, 1938.

PETRIDES, M. AND PANDYA, D. N. Comparative architectonic analysis of the human and macaque frontal cortex. In: *Handbook of Neuropsychology*, edited by J. Grafman and F. Boller. Amsterdam: Elsevier, 1995,

PICARD, N. AND STRICK, P. L. Motor areas of the medial wall: a review of their location and functional activation. *Cerebral Cortex* 6: 342–353, 1996.

PIETRZYK, U., HERHOLZ, K., FINK, G. R., JACOBS, A., MIELKE, R., SLANSKY, I., WUERKER, M., AND HEISS, W.-D. Validation of a multi-purpose three-dimensional image registration technique. *J. Nuclear Med.* 35: 2011–2018, 1994.

PLAYFORD, E. D., JENKINS, I. H., PASSINGHAM, R. E., NUTT, J., FRACKOWIAK, R.S.J., AND BROOKS, D. J. Impaired mesial frontal and putamen activation in Parkinson's disease: a PET study. *Ann. Neurol.* 32: 151–161, 1992.

RAO, S. M., BINDER, R. J., BANDETTINI, P. A., HAMMEKE, T. A., YETKIN, F. Z., JESMANOWICZ, A., LISK, L. M., MORRIS, G. L., MUELLER, W. M., ESTKOWSKI, L. D., WONG, E. C., HAUGHTON, V. M., AND HYDE, J. S. Functional magnetic resonance imaging of complex human movements. *Neurology* 43: 2311–2318, 1993.

RAO, S. M., BINDER, J. R., HAMMEKE, T. A., BANDETTINI, P. A., BOBHOLZ, J. A., FROST, J. A., MYKLEBUST, B. M., JACOBSON, R. D., AND HYDE, J. S. Somatotopic mapping of the human primary motor cortex with functional magnetic resonance imaging. *Neurology* 45: 919–924, 1995.

REMY, P., ZILBOVICIUS, M., LEROY-WILLIG, A., SYROTA, A., AND SAMSON, Y. Movement- and Task-related activations of motor cortical areas: a positron emission tomographic study. *Ann. Neurol.* 36: 19–26, 1994.

RIZZOLATTI, G., CAMARDA, R., FOGASSI, L., GENTILUCCI, M., LUPPINO, G., AND MATELLI, M. Functional organization of inferior area 6 in the macaque monkey. II. Area F5 and the control of distal movements. *Exp. Brain Res.* 71: 491–507, 1988.

RIZZOLATTI, G., FADIGA, L., GALLESE, V., AND FOGASSI, L. Premotor cortex and the recognition of motor actions. *Cognit. Brain Res.* 3: 131–142, 1996.

RIZZOLATTI, G., GENTILUCCI, M., FOGASSI, L., LUPPINO, G., MATELLI, M., AND PONZONI-MAGGI, S. Neurons related to goal-directed motor acts in inferior area 6 of the macaque monkey. *Exp. Brain Res.* 67: 220–224, 1987.

ROLAND, P. E., GULYAS, B., AND SEITZ, R. J. Structures in the human brain participating in visual learning, tactile learning and motor learning. In: *Memory: Organization and Locus of Change*, edited by L. R. Squire, N. M. Weinberger, G. Lynch, and J. L. McGaugh. Oxford: Oxford University Press, 1991, p. 95–113.

ROLAND, P. E. AND ZILLES, K. Brain atlases—a new research tool. *Trends Neurosci.* 17: 458–467, 1994.

RUMEAU, C., TZOURIO, N., MURAYAMA, N., PERETTI-VITON, P., LEVRIER, O., JOLIOT, M., MAZOYER, B., AND SALAMON, G. Location of hand function in the sensorimotor cortex: MR and functional correlation. *Am. J. Neuroradiol.* 15: 567–572, 1994.

SANES, J. N., DONOGHUE, J. P., THANGARAJ, V., EDELMAN, R. R., AND WARACH, S. Shared neural substrates controlling hand movements in human motor cortex. *Science Wash. DC* 268: 1775–1777, 1995.

SCHLAUG, G., KNORR, U., AND SEITZ, R. J. Inter-subject variability of cerebral activations in acquiring a motor skill: a study with positron emission tomography. *Exp. Brain Res.* 98: 523–534, 1994.

SERENO, M. I., DALE, A. M., REPPAS, J. B., KWONG, K. K., BELLIVEAU, J. W., BRADY, T. J., ROSEN, B. R., AND TOOTELL, R.B.H. Borders of multiple visual areasin humans revealed by functional magnetic resonance imaging. *Science Wash. DC* 268: 889–893, 1995.

SHIPP, S., WATSON, J.D.G., FRACKOWIAK, R.S.J., AND ZEKI, S. Retinotopic maps in human prestriate visual cortex: the demarcation of areas V2 and V3. *Neuroimage* 2: 125–132, 1995.

SILBERSWEIG, D. A., STERN, E., FRITH, C. D., CAHILL, C., SCHNORR, L., GROOTONK, S., SPINKS, T., CLARK, J., FRACKOWIAK, R.S.J., AND JONES, T. Detection of thirty-second cognitive activations in single subjects with positron-emission-tomography: a new low-dose $H_2{}^{15}O$ regional cerebral blood flow three-dimensional imaging technique. *J. Cereb. Blood Flow Metab.* 13: 617–629, 1993.

SPINKS, T. J., JONES, T., BAILEY, D. L., TOWNSEND, D. W., GROOTONK, S., AND BLOOMFIELD, P. M. Physical performance of a positron tomograph for brain imaging with retractable septa. *Phys. Med. Biol.* 8: 1637–1655, 1992.

STEINMETZ, H., FUERST, G., AND FREUND, H. J. Cerebral cortical localization: application and validation of the proportional grid system in MR imaging. *J. Comp. Assist. Tomogr.* 13: 10–19, 1989.

STEPHAN, K. M., FINK, G. R., PASSINGHAM, R. E., SILBERSWEIG, D., CEBALLOS-BAUMANN, A. O., FRITH, C. D., AND FRACKOWIAK, R.S.J. Imagining the execution of movements. *J. Neurophysiol*. 73: 373–386, 1995.

TALAIRACH, J. AND TOURNOUX, P. *Coplanar Stereotaxic Atlas Of The Human Brain.* Stuttgart: Thieme, 1988.

TOWNSEND, D. W., GEISSBULLER, A., DEFRISE, M., HOFFMAN, E. J., SPINKS, T. J., BAILEY, D. L., GILARDI, M.-C., AND JONES, T. Fully three-dimensional reconstruction for a PET camera with retractable septa. *IEEE Trans. Med. Imaging* 10: 505–512, 1991.

TOYOSHIMA, M. AND SAKAI, H. Exact cortical extent of the origins of the corticospinal tract (CST) and the quantitative contribution of the CST in different cytoarchitectonic areas. A study with horseradish peroxidase in the monkey. *J. Hirnforsch*. 23: 257–269, 1981.

VAN ESSEN, D. C., FELLEMAN, D. J., DEYOE, E. A., AND KNIERIM, J. J. Probing the primate visual cortex: pathways and perspectives. In: *Functional Organization of the Human Visual Cortex*, edited by B. Gulyas, D. Ottoson, and P. E. Roland. Oxford: Pergamon, 1993, p. 29–42.

VOGT, B. A., NIMCHINSKY, E. A., VOGT, L. J., AND HOF, P. R. Human cingulate cortex: surface features, flat maps, and cytoarchitecture. *J. Comp. Neurol.* 359: 490–506, 1995.

WATSON, J.D.G., MYERS, R., FRACKOWIAK, R.S.J., HAJNAL, J. V., WOODS, R. P., MAZZIOTTA, J. C., SHIPP, S., AND ZEKI, S. Area V5 of the human brain: evidence from a combined study using positron emission tomography and magnetic resonance imaging. *Cereb. Cortex* 3: 79–94, 1993.

WEILLER, C., CHOLLET, F., FRISTON, K. J., WISE, R.J.S., AND FRACKOWIAK, R.S.J. Functional reorganization of the brain in recovery from striatocapsular infarction in man. *Ann. Neurol.* 31: 463–472, 1992.

WIESENDANGER, M., ROUILLER, E. M., KAZENNIKOV, O., AND PERRIG, S. Is the supplementary motor area a bilaterally organized system? In: *Supplementary Sensorimotor Area*, edited by H. O. Lueders. Philadelphia: Lippincott-Raven, 1996, p. 85–94.

WISE, S. P. Corticospinal efferents of the supplementary sensorimotor area in relation to the primary motor area. In: *Supplementary Sensorimotor Area*, edited by H. O. Lueders. Philadephia: Lippincott-Raven, 1996, p. 71–84.

WISE, S. P., DI PELLEGRINO, G., AND BOUSSAOUD, D. The premotor cortex and nonstandard sensorimotor mapping. *Can. J. Physiol. Pharmacol*. (In press).

WOODS, R. P., CHERRY, S. R., AND MAZZIOTTA, J. C. A rapid automated algorithm for accurately aligning and reslicing positron emission tomography images. *J. Comp. Assist. Tomogr.* 16: 620–633, 1992.

WOODS, R. P., MAZZIOTTA, J. C., AND CHERRY, S. R. MRI-PET registration with automated algorithm. *J. Comp. Assist. Tomogr.* 17: 536–546, 1993.

WOOLSEY, C. N., SETTLAGE, P. H., MEYER, D. R., SPENCER, W., PINTO-HAMUY, T., AND TRAVIS, M. Pattern of localization in precentral and ''supplementary'' motor area and their relation to the concept of a premotor cortex. *Assoc. Res. Nerv. Ment. Dis.* 30: 238–264, 1952.

ZEKI, S. *A Vision Of The Brain.* Oxford: Blackwell Scientific Publication, 1993.

ZEKI, S., WATSON, J.D.G., LUECK, C. J., FRISTON, K. J., KENNARD, C., AND FRACKOWIAK, R.S.J. A direct demonstration of functional specialization in human visual cortex. *J. Neurosci*. 11: 641–649, 1991.

ZILLES, K., SCHLAUG, G., GEYER, S., LUPPINO, G., MATELLI, M., QUE, M., SCHLEICHER, A., AND SCHORMANN, T. Anatomy and transmitter receptors of the supplementary motor area in the human and non-human primate brain. In: *Supplementary Sensorimotor Area*, edited by H. O. Lueders. Philadelphia: Lippincott-Raven, 1996a, p. 29–44.

ZILLES, K., SCHLAUG, G., MATELLI, M., LUPPINO, G., SCHLEICHER, A., QU, M., DABRINGHAUS, A., SEITZ, R., AND ROLAND, P. E. Mapping of human and macaque sensorimotor areas by integrating architectonic, transmitter receptor, MRI and PET data. *J. Anat.* 187: 515–537, 1996b.